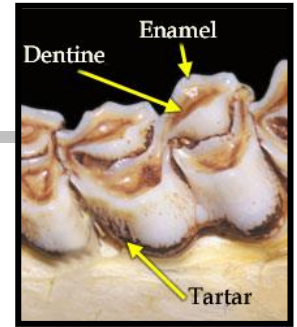


Aging Deer Jawbones

When aging a deer, only examine the lower jaw bone. Be sure to keep in mind:

- a **cusp** is a point or projection on the chewing surface of a tooth
- the 1st three teeth are premolars.
- the last three teeth are molars.
- **Dentine**= brown “stripe” on top of teeth



1. Four to five teeth present (premolars and molars); *Figure A*....**Fawn (6 mo or less)**
1. Six teeth present.....**2**
2. 3rd tooth tricuspid; *Figure B*.....**1.5yr old (17mo)**
2. 3rd tooth bicuspid.....**3**
3. 3rd tooth (bicuspid premolar) has no wear or dentine evident and 6th tooth (molar) has no wear or dentine evident and may not be fully erupted; *Figure C*.....**1.5yr old (18 mo)**
3. 3rd tooth (bicuspid premolar) exhibits signs of wear and dentine “stripe” is evident and 6th tooth is worn with dentine “stripe” evident; *Figure D*.....**2.5+yr old**

