

Key to Common Mammal Skulls

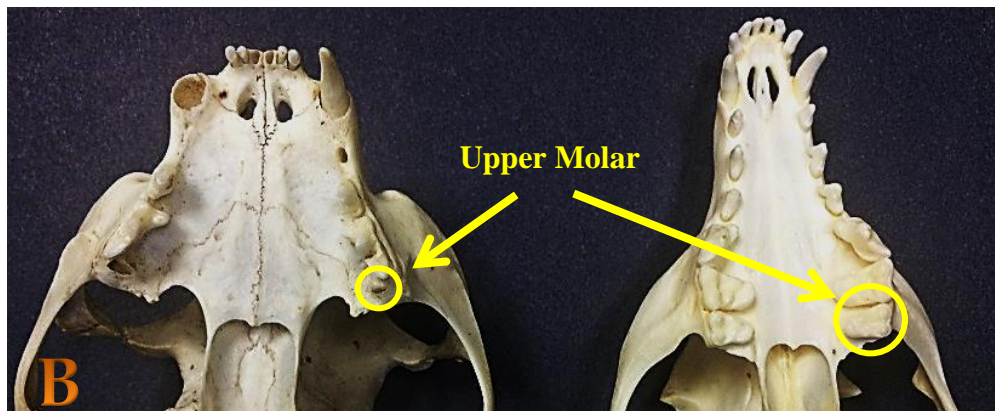
Kerry Wixted

- 1. Canines present2
- 1. Canines absent **Section A**
- 2. Incisors 5/4 and large sagittal ridge present (Figure A).....**Opossum**
- 2. Incisors not 5/4.....3



By Dawson @ en.wikipedia, CC BY-SA 2.5

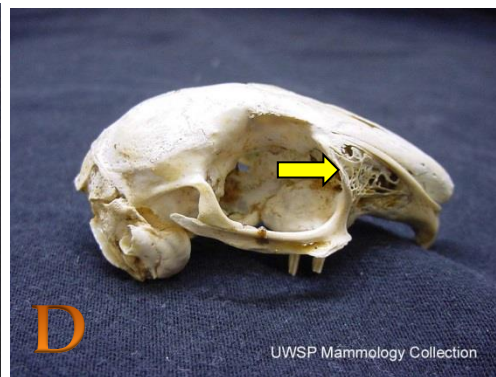

- 3. Rostrum short. Upper molar reduced and peg-like (Fig. B, left)4
- 3. Rostrum short or long. Upper molar(s) large and robust (Fig. B, right)5



- 4. Premolars 3/2; greatest length of skull 77-101 mm.....**House cat**
- 4. Premolars 2/2; greatest length of skull over 101 mm.....**Bobcat**
- 5. Post-orbital process in front of skull midpoint; Molars 1/2 or 2/2.....6
- 5. Post-orbital process at or near skull midpoint; Molars 2/3.....**Section B**
- 6. 4-5 upper cheek teeth with less than 40 teeth total **Section C**
- 6. 6 or more upper cheek teeth with 40-42 teeth total7
- 7. Greatest length of skull less than 200 mm.....**Raccoon**
- 7. Greatest length of skull more than 200 mm.....**Black bear**

Section A: Deer, Rabbits and Rodents

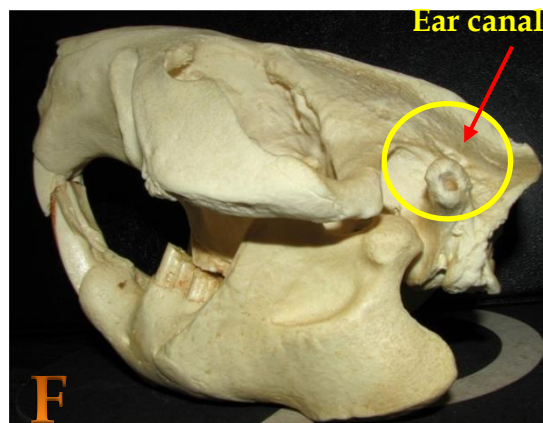
- 1. Upper incisors present.....2
- 1. Upper incisors absent..... **White-tailed deer**
- 2. Upper incisors 4 or 6; rostral fenestra present (Figures C & D)..... **Eastern cottontail**
- 2. Upper incisors less than 4; rostral fenestra absent.....3



- 3. Post-orbital process sharply pointed.....4
- 3. Post-orbital process not sharply pointed or absent.....6
- 4. Greatest length of skull greater than 76 mm..... **Groundhog**
- 4. Greatest length of skull less than 76 mm.....5
- 5. U-shaped temporal ridges form a small sagittal crest (Fig. E)..... **Eastern fox squirrel**
- 5. Temporal ridges not U-shaped; sagittal crest absent..... **Eastern gray squirrel**
- 6. Infraorbital canals round and almost as large as orbit.....7
- 6. Infraorbital canals often slit-like and smaller than orbit.....8
- 7. Paraoccipital process does not extend beyond auditory bullae..... **Porcupine**
- 7. Paraoccipital process extends beyond auditory bullae..... **Nutria**
- 8. Ear canals long and pointed upward (Fig. F)..... **Beaver**
- 8. Ear canals short and not pointed upward..... **Muskrat**



By: accipitereye, Flickr CC by SA 2.0



Skull Key 2

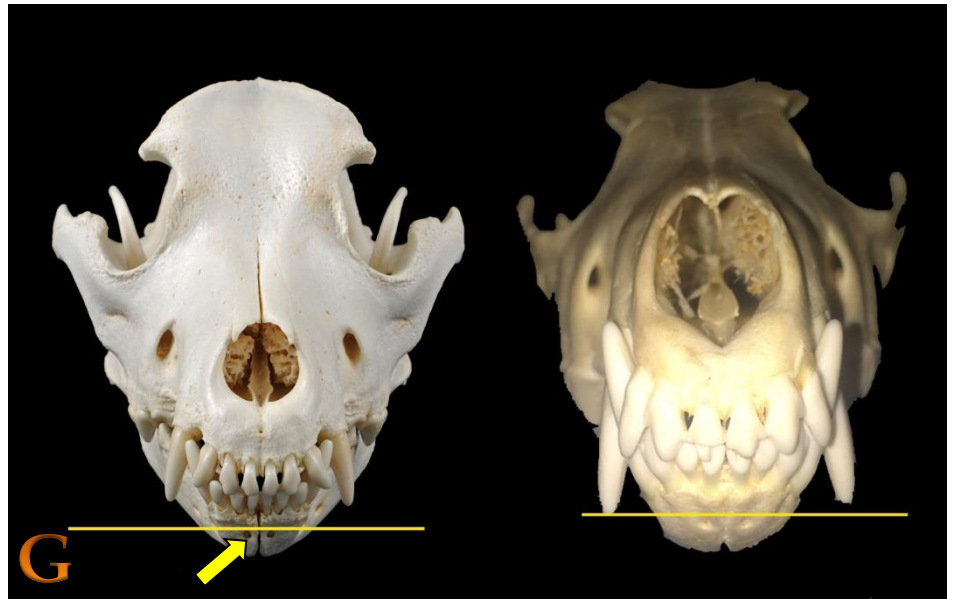
Section B: Canids

Canids are in the Order Carnivora. The Canidae family contains wolves, coyotes and foxes. Worldwide, there are about 34 species of Canids, 8 of which occur in North America.

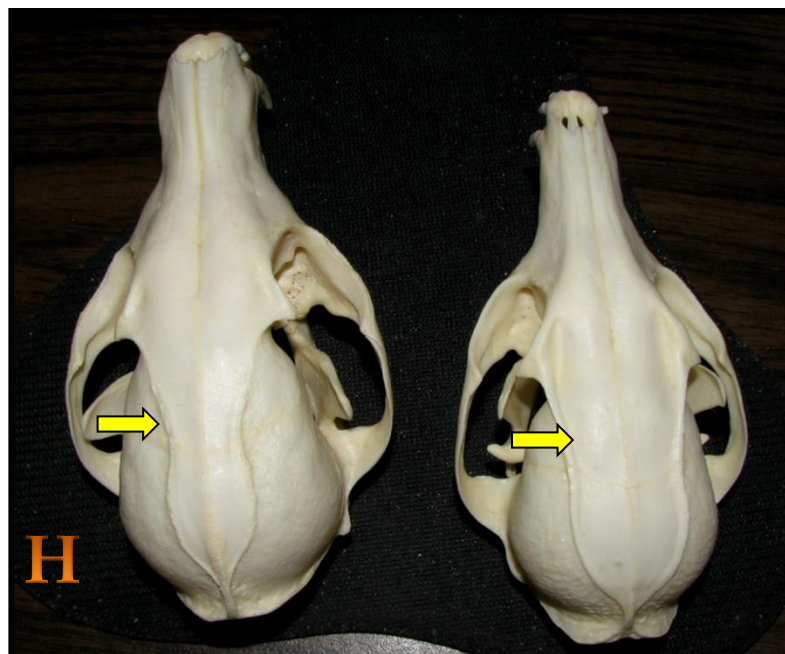
- 1. Greatest length of skull greater than 170 mm.....2
- 1. Greatest length of skull less than 170 mm.....3

2. Canines do not extend to the line across the mandibular mental foramina (Fig. G, left).....**Domestic dog**

2. Canines at or below the line across the mandibular mental foramina (Fig. G, right).....**Coyote**

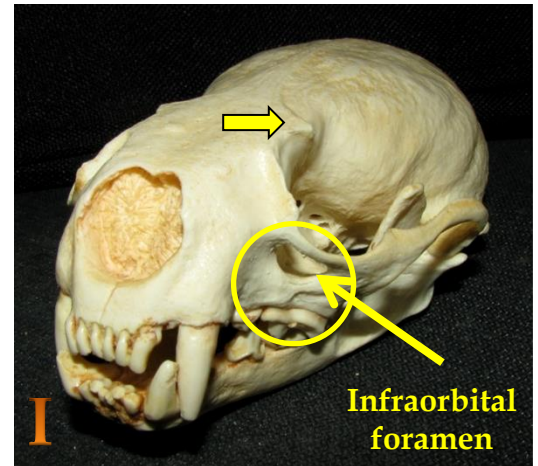


- 3. Temporal ridges on top of skull form a V-shape (Fig. H, left).....**Red fox**
- 3. Temporal ridges on top of skull from a U-shape (Fig. H, right).....**Gray fox**

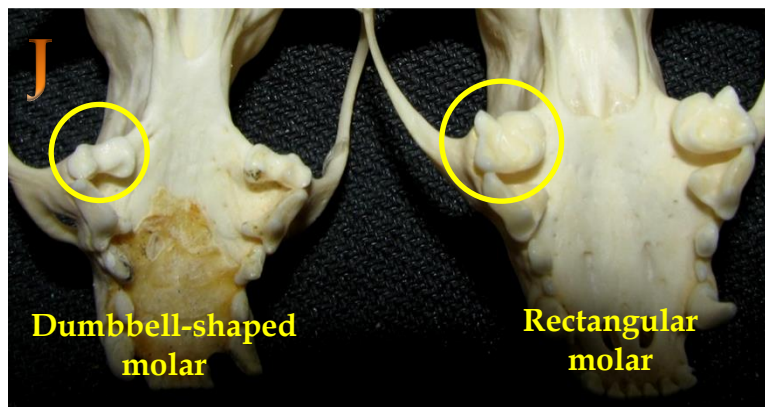


Section C: Mustelids & Skunks

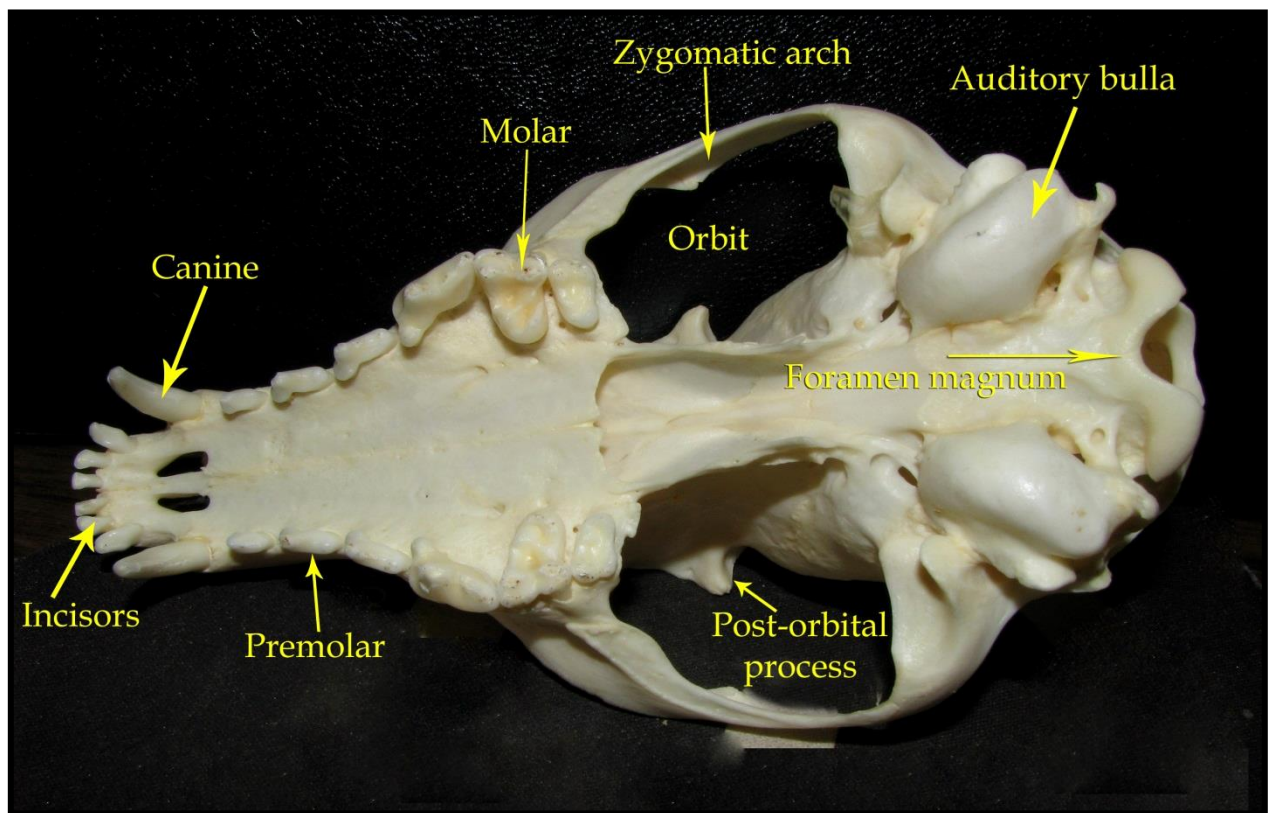
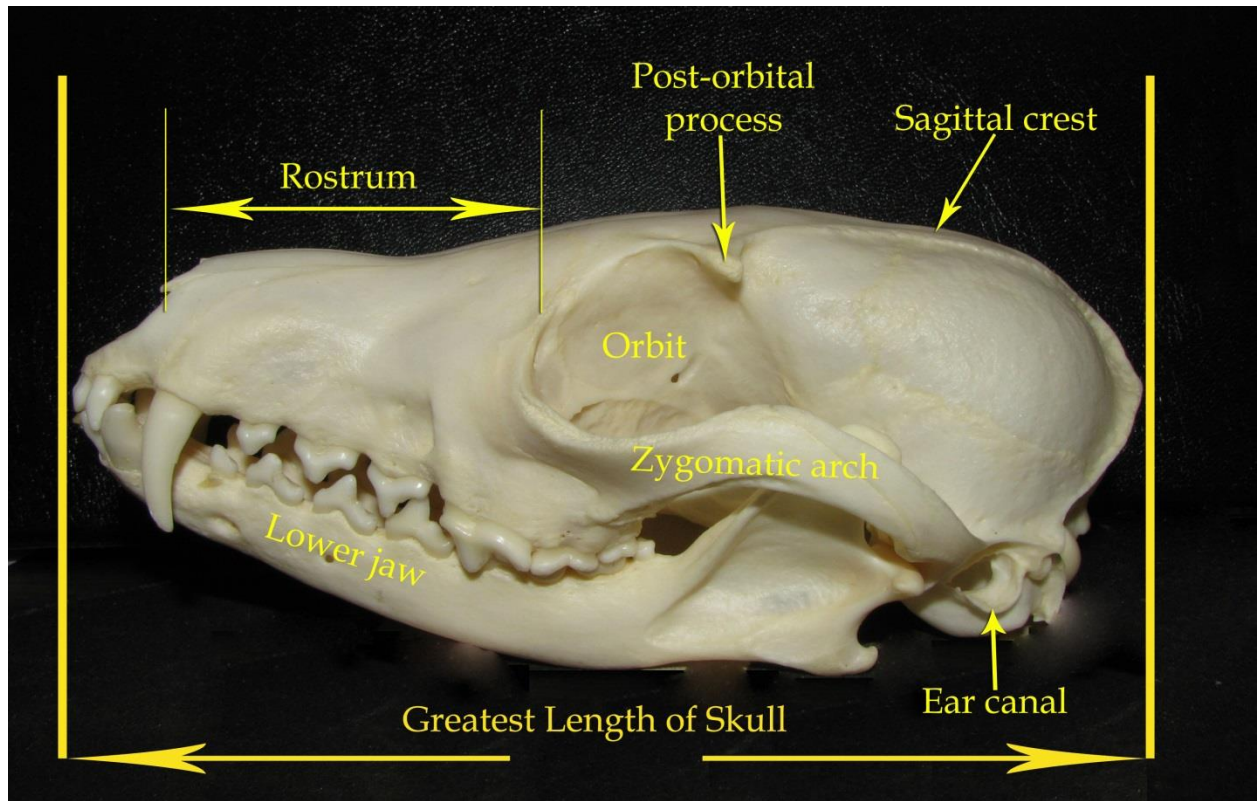
The Family Mustelidae contains weasels and allies. Mustelids have a special pair of teeth known as the carnassials. Carnassial teeth are a pair of blade-like teeth (last upper molar and first lower molar) that exhibit a shearing action. This set of teeth is found in most carnivores, but those on Mustelids are extremely well-developed. Skunks were once part of the mustelid family but are now in their own group.



- 1. Post-orbital process well developed; infraorbital foramen greater than 8mm in diameter (Fig. I).....**River otter**
- 1. Post-orbital process lacking to moderately developed; infraorbital foramen less than 8mm in diameter2
- 2. 5 upper cheek teeth per side; premolars 4/4.....**Fisher**
- 2. 4 upper cheek teeth per side; premolars 2/3 or 3/3.....3
- 3. Upper molar dumbbell-shaped (Fig. J, left); auditory bulla prominent, elongated.....4
- 3. Upper molar rectangular-shaped (Fig. J, right); auditory bulla flat and not elongated..... **Striped skunk**
- 4. Skull over 58mm long.....**Mink**
- 4. Skull 40-58mm long.....**Long-tailed weasel**



Mammal Skull Index



Glossary of Terms

- **Anterior-** front of skull or lower jaw
- **Auditory bulla-** bony capsule enclosing middle ear
- **Canine-** elongate, unicuspid tooth
- **Carnassial teeth-** pair of bladelike teeth (last upper molar and first lower molar) that exhibit a shearing action
- **Cheek teeth-** combination of premolars and molars
- **Dental formula-** numerical representation of the number of each kind of tooth on one side of the upper and one side of the lower jaw
 - **Example:** The statement 'incisors 5/4' means that there are 5 incisors on top and 4 incisors on the bottom for each side of the jaw
- **Diastema-** a gap or space in the jaw between teeth; used most often to denote gap between incisors and cheek teeth in rodents
- **Foramen magnum-** large opening at the back of a skull which the spinal cord goes through
- **Greatest length of skull-** length from tip of rostrum to the posteriormost part of the skull
- **Incisors-** anterior-most teeth (front teeth) of mammals
- **Infraorbital foramen-** opening below orbit (eye socket)
- **Mandibular mental foramen-** foramina (openings) located on the anterior surface of the mandible
- **Molar-** teeth located after premolars
- **Orbit-** eye socket
- **Paraoccipital process-** a downward-projecting spur from the base of the skull which attaches the muscle used in opening the lower jaw
- **Posterior-** back of skull or lower jaw
- **Post-orbital process-** bony projection
- **Premolar-** teeth situated between canines and molars
- **Rostrum-** distance from end of nostrils to orbit
- **Sagittal crest-** raised bony ridge on middle of cranium
- **Temporal ridge-** any of four nearly parallel curved ridges or lines situated two on each side of the skull and chiefly on the parietal bone
- **Zygomatic arch-** arch of bone protecting the orbit (eye socket)